



Contents lists available at ScienceDirect

Journal of Pediatric Surgery

journal homepage: [www.elsevier.com/locate/jped surg](http://www.elsevier.com/locate/jped surg)

## Operative management of pediatric ovarian tumors and the challenge of fertility-preservation: Results from the UK CCLG Surgeons Cancer Group Nationwide Study ☆☆☆★☆☆☆☆

Sarah Braungart<sup>a,b,\*</sup>, CCLG Surgeons Collaborators<sup>c</sup>, Ross J Craigie<sup>a</sup>, Paul Farrelly<sup>a</sup>, Paul D Losty<sup>b,d</sup>

<sup>a</sup> Department of Paediatric Surgery, Royal Manchester Children's Hospital, Manchester, UK

<sup>b</sup> Department of Paediatric Surgery, Alder Hey Children's Hospital, Liverpool, UK

<sup>c</sup> CCLG Surgeons Cancer Group, Children's Cancer and Leukaemia Group, Leicester, UK

<sup>d</sup> University of Liverpool, Liverpool L69 3BX, UK

### ARTICLE INFO

#### Article history:

Received 3 November 2019

Received in revised form 25 February 2020

Accepted 26 February 2020

Available online xxxx

#### Key words:

Ovarian tumor

Ovarian teratoma

Ovary-sparing surgery

Minimally invasive surgery

Fertility preservation

Pediatric

Adolescent

UK CCLG surgeons

### ABSTRACT

**Background:** Ovarian tumors in the pediatric age group are rare. A significant number of children with ovarian mass lesions present "out of hours" as surgical emergencies, and surgical management does not always involve a surgical oncologist. This multicenter study reports how the mode of clinical presentation may influence (i) operation (conventional open vs minimally invasive surgery (MIS)) and (ii) examines if young females presenting as surgical emergency(s) are more likely to undergo total oophorectomy or ovarian sparing surgery.

**Methods:** Retrospective multicenter study amongst UK pediatric surgical oncology centers. Females <16 years with diagnosis of ovarian tumor from 2006 to 2016 were included. Functional/neonatal ovarian cysts were excluded.

**Results:** Three hundred ten patients with ovarian tumors treated at 12 surgical oncology centers were identified. Mean age at surgery was 11 years [IQR 8–14]. Most common diagnosis were mature teratoma (57%, 177 cases), immature teratoma (10.9%, 34 cases) and cystadenoma (12%, 36 cases). Seventy percent (217) of cases were performed as open procedures. Thirty percent (94) of children underwent MIS.

Tumors were significantly smaller in children who underwent MIS. Median tumor size in the laparoscopic group was 6 cm compared to 11 cm in the open group ( $p < 0.00001$ ). Children who underwent MIS were significantly more likely to have ovary sparing surgery.

**Conclusion:** This UK nationwide study demonstrates that ovary-sparing surgery and minimally invasive surgery are still infrequently deployed by pediatric surgeons in the UK. Patients with smaller tumors were more likely to undergo MIS, and more frequently underwent ovary-sparing surgery. In view of the implications on fertility and hormonal health caused by unilateral oophorectomy, it is time to review this current practise and agree consensus guidelines to reduce rates of unnecessary oophorectomy.

**Level of evidence statement:** This is a level II evidence study. It is a retrospective multicentre collaborative study, which summarizes data from a national cohort of children.

© 2020 Published by Elsevier Inc.

Ovarian tumors in children are rare. Overall incidence is estimated at 2.6 per 100,000 girls, but varies depending on patient age and histological diagnosis [1–3]. 90% of pediatric ovarian tumors are classed as

☆ CCLG Surgeons Collaborators are listed in Annex A.

☆☆ This manuscript was originally presented as an oral presentation at SIOP IPSO in Kyoto, Japan, in November 2018.

★ Sources of Support/ Funding: This research did not receive any specific grant from funding agencies in the public, commercial, or not-for-profit sectors.

★★ Acknowledgments: None.

☆☆☆ Conflicts of Interest: None.

\* Corresponding author at: Specialty Registrar in Paediatric Surgery, Health Education North West England UK, 1120 XQ7 Building, Taylerson Street South, Manchester, M5 3FY, UK.

E-mail address: [sarah.braungart@doctors.org.uk](mailto:sarah.braungart@doctors.org.uk) (S. Braungart).

benign. Mature ovarian teratoma, a slow-growing tumor with the potential for malignant transformation, constitutes the most common benign prepubertal ovarian neoplasm [2]. Prognosis is thought to be excellent following complete resection and for a long time, total unilateral oophorectomy has been generally performed in these cases [4].

Little is known on the true incidence of recurrence and metachronous disease in benign ovarian tumors. Most studies on this subject are retrospective and only include few patients. Nevertheless, they all suggest that there is a risk of metachronous disease occurring in the contralateral ovary; reported incidence varying between 5.7%–23% [5–7]. These findings suggest that children undergoing unilateral oophorectomy for an ovarian tumor are at significant risk of losing the contralateral ovary in case of a metachronous tumor.

<https://doi.org/10.1016/j.jpedsurg.2020.02.057>

0022-3468/© 2020 Published by Elsevier Inc.

Please cite this article as: S. Braungart, R.J. Craigie, P. Farrelly, et al., Operative management of pediatric ovarian tumors and the challenge of fertility-preservation: Results from the..., Journal of Pediatric Surgery, <https://doi.org/10.1016/j.jpedsurg.2020.02.057>

More evidence has become available on the detrimental impact of oophorectomy on female fertility and hormonal health. Ovary-sparing surgery and use of minimally invasive surgery have therefore gained increasing popularity. The literature shows, however, that these techniques are much more commonly employed by adolescent gynecologists than pediatric surgeons [8].

A recent national survey amongst UK pediatric surgeons demonstrated that – unlike other tumors – ovarian tumors are frequently treated by non-oncology surgeons. This may partially be explained by the fact that children with ovarian tumors more commonly present out of hours, in an emergency situation with acute abdominal pain or suspicion of ovarian torsion. The survey also showed that most non-oncology surgeons treat less than two ovarian tumors per year and raises questions if this really is best practise management for these children [9].

We therefore aimed to investigate in a UK nationwide multicentre study if children with ovarian tumors who presented as emergency (s) were more likely to undergo total oophorectomy and conventional open surgery, than patients who were referred and managed on an elective basis by specialty surgical services.

## 1. Methods

A nationwide study facilitated through the Surgical Specialty Group of the UK Children's Cancer and Leukemia Group (CCLG) was performed. The study was registered as Audit 7705 with the Royal Manchester Children's Hospital as Lead coordinating centre. Participation was open to all pediatric surgical oncology centres in the United Kingdom (UK) on a voluntary basis.

A standardized data collection form was distributed amongst participating centres (Fig. 1). Female patients <16 years with an index diagnosis of ovarian tumor from 2006 to 2016 were included. Patients with functional cysts and neonatal ovarian cysts were excluded. For statistical analysis, cumulative tables were created using Microsoft Excel®. Statistical significance was determined using the online tool "Social Science Statistics®" Calculator [22], employing the two-tailed Mann Whitney test, and the Fisher's exact test respectively, as indicated.

## 2. Results

Twelve out of the 22 UK CCLG registered pediatric surgical oncology centres participated in the study, resulting in a response rate of 55%. Three-hundred ten patients were identified who underwent resection of an ovarian tumor between 2006 and 2016.

One hundred forty-eight (47.7%) patients presented as surgical emergencies, meaning the child presented to the emergency department with acute symptoms. 160 (51.6%) cases had elective presentation. Elective presentation was defined as General Practitioner referral to hospital outpatient clinics. Mode of referral was unclear in 2 patients.

Median age at surgery was 11 years [IQR 8–14 years]. Most common diagnoses were mature teratoma (57%, 176 cases), immature teratoma (11%, 34 cases) and serous cystadenoma (7.7%, 24 cases) [21].

Overall, 70% (217) of cases were performed as conventional open procedures. 30% (94) of children underwent minimally invasive surgery (MIS). Out of these cases 11% (10) were commenced as laparoscopic procedure(s) and subsequently converted to an open operation.

Mode of presentation – i.e. whether a patient presented as an emergency or was referred electively – did not significantly influence the choice of surgery. 37.2% of all MIS cases were emergency procedures, and 31.5% of all open cases were emergency procedures ( $p = 0.35$ ; Fisher's exact test).

Tumors were smaller in children who underwent MIS. Median tumor size in the laparoscopic group was 6 cm [IQR 5.7; 10], compared to 11 cm [IQR 7; 19] in the open group (Fig. 2a). This result was statistically significant ( $p < 0.00001$ ; Mann Whitney test, two-tailed). Overall

children who underwent MIS were significantly more likely to have ovary-sparing surgery ( $p < 0.00001$ ; Fisher's exact test); (Fig. 2b).

21% (22) of children who presented as an emergency had ovary-sparing surgery, compared to 23% (48) of children that were treated on an elective basis. This was not significant ( $p = 0.77$ ; Fisher's exact test).

## 3. Discussion

The main challenge for the pediatric surgeon in the management of ovarian tumors lies in finding the right balance between optimal tumor resection and maximal fertility preservation. Recent large population-based cohort studies have demonstrated significant long-term health implications of oophorectomy on female fertility as well as psychological and hormonal health [10].

Detrimental effects can be seen following both unilateral or bilateral oophorectomy. Yasui et al. showed that unilateral oophorectomy increases the risk of premature ovarian failure and early menopause (i.e. menopause under the age of 45 years) [10]. Estrogen deficiency in the first decades of life increases the risk for cardiovascular disease, and it is well established that early menopause results in increased risk for osteoporosis and bone fractures [11,12].

In addition, a recent meta-analysis confirmed that oophorectomy is associated with an increased overall mortality, which is not solely due to ischaemic heart disease [13].

Interestingly, oophorectomy has also been shown to effect cognitive function, and is associated with an increased risk for dementia and Parkinson's disease [14]. The overall effects on quality of life, psychological well-being and sexual function are less well researched, but one can imagine that these are effected, too. Of further concern, only some (but not all) of the above negative outcomes can be influenced by estrogen replacement therapy [14].

These findings demonstrate that preservation of healthy ovarian tissue must be of great importance to surgeons dealing with ovarian pathology. Only 22% of children in our study underwent ovary-sparing surgery, regardless of mode of presentation. Previous studies have shown that adolescent gynecologists are more likely to undertake ovary-sparing surgery, and total oophorectomy is more common in children under 14 years [8]; [15]. Management of germ cell tumors in the United Kingdom (UK) is facilitated by the Children's Cancer and Leukemia Group's (CCLG) guidelines, yet – in terms of managing mature teratoma – these are open to varied interpretation. CCLG guidance advises that "in strongly suspected ovarian mature teratoma it is reasonable to attempt fertility preserving surgery with resection of tumor only, rather than oophorectomy." [16]. No recommendation is provided whatsoever on the use of minimally invasive surgery – hence it is not surprising that the vast majority of cases in our study underwent conventional open surgery. Guidelines by the Royal College of Obstetricians and Gynecologists clearly favor minimally invasive surgery because of decreased post-operative morbidity, shorter patient recovery time and earlier hospital discharge [17]. However it is wholly acknowledged that minimally invasive surgery may be of little benefit, or not even feasible in large ovarian neoplastic lesions. This is the case for example in slim, prepubertal girls with large solid lesions, where a reasonable sized incision is required at the end of the procedure to extract the tumor, whether or not the main part of the procedure was performed laparoscopically [17,18].

Chemical peritonitis as a consequence of intraoperative tumor spillage following ovarian teratoma resection has been of concern for a long time [19]. However, when reviewing the literature more closely, it must be acknowledged that there is very little evidence available, most of which stems from the adult literature [20]. A systematic review including 14 studies of minimally invasive surgery ovarian teratoma resection with notably high spillage rates concluded that overall the risk for chemical peritonitis lies at 0.2% [20]. More research is therefore clearly

## Retrospective Ovarian Tumour Study

Centre: [\[Click here to enter text\]](#)

Please email completed form to [sarah.braungart@mft.nhs.uk](mailto:sarah.braungart@mft.nhs.uk)

### Patient-related data

Patient identifier (e.g. Manchester01)	<a href="#">Click here to enter text.</a>
Age at presentation (years, months, days)	<a href="#">Click here to enter text.</a>
Comorbidities	<a href="#">Click here to enter text.</a>
Past medical history	<a href="#">Click here to enter text.</a>
Family history of ovarian cancer:	<input type="checkbox"/> Yes <input type="checkbox"/> No
If yes, please specify relation to patient and age of relative on detection: <a href="#">Click here to enter text.</a>	

### Presentation

Type of presentation:	Out of hours <input type="checkbox"/> Elective <input type="checkbox"/>
If elective - referred from? (e.g. GP, other hospital)	<a href="#">Click here to enter text.</a>

### Operative details

Age at operation (years, months, days): <a href="#">Click here to enter text.</a>	Elective/ Planned: <input checked="" type="checkbox"/> Emergency procedure: <input checked="" type="checkbox"/>
Was the procedure: Laparoscopic <input type="checkbox"/> Or Open <input type="checkbox"/>	
Was the procedure: Total oophorectomy: <input type="checkbox"/> Ovary-sparing surgery <input type="checkbox"/> Simple derotation of cyst and secondary resection <input type="checkbox"/>	
If laparoscopic procedure – was second incision (such as Pfannenstiel) required for tumour retrieval? Yes <input type="checkbox"/> No <input type="checkbox"/>	
Were the operative findings consistent with ovarian torsion? Yes <input type="checkbox"/> No <input type="checkbox"/>	

### Histology

Histology:	<a href="#">Click here to enter text.</a>
Tumour size (largest diameter, cm):	<a href="#">Click here to enter text.</a>

**Recurrence of tumour** (defined as tumour recurring in the same ovary that had previous resection, hence only possible if patient had previous ovary-sparing surgery):

Recurrent tumour:	Yes <input type="checkbox"/> No <input type="checkbox"/>
Date of detection of recurrence:	<a href="#">Click here to enter text.</a>
Mode of detection of recurrence:	Routine follow-up <input type="checkbox"/> Re-presentation <input type="checkbox"/> Re-referral <input type="checkbox"/>
Further surgery undertaken: Yes <input type="checkbox"/> No <input type="checkbox"/>	
If yes, please specify: <a href="#">Click here to enter text.</a>	

**Metachronous tumour** (defined as tumour occurred in contralateral ovary after the first tumour on the first ovary):

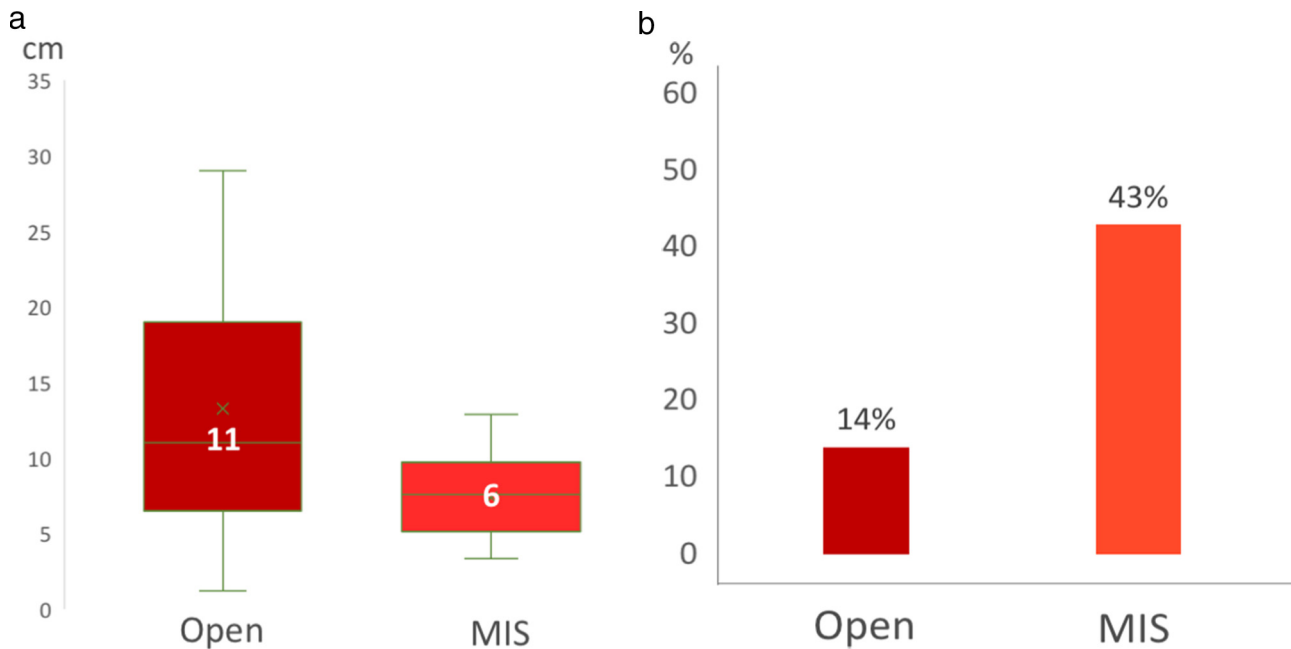
Metachronous tumour	Yes <input type="checkbox"/> No <input type="checkbox"/>
Date of detection of metachronous tumour:	<a href="#">Click here to enter text.</a>
Mode of detection of recurrence:	Routine follow-up <input type="checkbox"/> Re-present <input type="checkbox"/> Re-referral <input type="checkbox"/>
Further surgery undertaken? Yes <input type="checkbox"/> No <input type="checkbox"/>	
If yes, please specify: <a href="#">Click here to enter text.</a>	

Fig. 1. Data collection form.

required to establish the true impact of intraoperative spillage in surgery for mature ovarian teratoma.

In this study the total number of cases treated by minimally invasive surgery, and the total number of cases undergoing ovary-sparing surgery were small compared to the group of female patients who underwent open surgery and total oophorectomy. This was not influenced by the mode of clinical presentation of the patient. In view of the impact of total oophorectomy on a girl's future fertility and hormonal health and the possibility of late occurrence of metachronous

disease, it is time to review current surgical practice and agree an evidence based 'best practice' strategy. In the emergency setting, we recommend the following approach, which may aid pediatric surgeons without special interest in pediatric surgical oncology in their decision making, should they be faced with a girl presenting in the setting of potential ovarian torsion out of hours. The safest approach, if a large black ovarian mass is discovered, is simple derotation of the torqued ovary and closure. In case of a simple torsion, this allows for preservation of any viable ovarian tissue, in case of an ovarian tumor it allows time for an



**Fig. 2.** a: Tumors were significantly smaller in children who underwent MIS. Median tumor size in the MIS group was 6 cm [IQR 5.7; 10], compared to 11 cm [IQR 7; 19] in the open group. This result was statistically significant ( $p < 0.00001$ ; Mann Whitney test, two-tailed). [MIS = minimally invasive surgery] b: Patients who underwent MIS were significantly more likely to have ovary-sparing surgery ( $p < 0.00001$ ; Fisher's exact test) (Graph 2). [MIS = minimally invasive surgery].

adequate work-up, including tumor markers, possibly further imaging and subsequent management by a pediatric surgical oncologist.

Considering the recent evidence on long-term effects of oophorectomy, we think it is imperative to raise awareness of the importance of ovarian preservation amongst pediatric surgeons. Similar to other tumors, we recommend that these cases should be managed by surgeons with an expertise in ovary-sparing surgery. This will also aid the pre-operative counseling to allow a meaningful and frank discussion with patient(s), family(s) and the surgeon. The conversation should weigh up the risks of recurrence/ metachronous disease and implications of oophorectomy, in order to agree a personalized management strategy for each patient.

#### 4. Conclusion

This UK nationwide study demonstrates that ovary-sparing surgery and minimally invasive surgery are still infrequently deployed by pediatric surgeons in the UK. In view of the implications on fertility and hormonal health caused by unilateral oophorectomy, we need to review current practice. Ovary-sparing surgery by trained surgical specialists taking appropriate precautions to avoid tumor spillage should be performed in benign ovarian disease wherever possible.

#### Appendix A. CCLG Collaborators in alphabetical order

James Andrews, Royal Hospital for Children Glasgow  
 Katherine Burnand, Great Ormond Street Hospital  
 Alison Campbell, Sheffield Children's Hospital  
 David Colvin, Royal Belfast Hospital for Sick Children  
 Kate Cross, Great Ormond Street Hospital  
 Fiona Dawson, St George's Hospital London  
 Alistair Dick, Royal Belfast Hospital for Sick Children  
 Evelyn Ervine, Royal Belfast Hospital for Sick Children  
 Ross Fisher, Sheffield Children's Hospital  
 Hany Gabra, Newcastle Children's Hospital  
 Philip Hammond, Royal Hospital for Sick Children Edinburgh

Kamal Kuti, Royal Hospital for Sick Children Edinburgh  
 Michael Jacovides, Royal Hospital for Children, Glasgow  
 Claire Jackson, Addenbrookes Hospital Cambridge  
 Khokila Lakoo, Oxford Children's Hospital  
 Ahmed Mohamed, Newcastle Children's Hospital  
 Mohamed Mostafa, Bristol Children's Hospital  
 Bruce Okoye, St George's Hospital London  
 Mark Powis, Leeds Children's Hospital  
 Timothy Rogers, Bristol Children's Hospital  
 Andrew Ross, Oxford Children's Hospital  
 Gillian Winter, Royal Aberdeen Children's Hospital

#### References

- [1] Skinner MA, Schlatter MG, Heifetz SA, et al. Ovarian neoplasms in children. *Arch Surg* 1993;128:849–53 [discussion 53–4].
- [2] Oelschlager AM, Gow KW, Morse CB, et al. Management of large ovarian neoplasms in pediatric and adolescent females. *J Pediatr Adolesc Gynecol* 2016;29:88–94.
- [3] Lindfors O. Primary ovarian neoplasms in infants and children. A study of 81 cases diagnosed in Finland and Sweden. *Ann Chir Gynaecol Fenn Suppl* 1971;177:1–66.
- [4] Renaud EJ, Sømme S, Islam S, et al. Ovarian masses in the child and adolescent: an American pediatric surgical association outcomes and evidence-based practice committee systematic review. *J Pediatr Surg* 2019;54(3):369–77.
- [5] Taskinen S, Urtane A, Fagerholm R. Metachronous benign ovarian tumors are not uncommon in children. *J Pediatr Surg* 2014;49:543–5.
- [6] Rogers EM, Allen L, Kives S. The recurrence rate of ovarian dermoid cysts in pediatric and adolescent girls. *J Pediatr Adolesc Gynecol* 2014;27(4):222–6.
- [7] Chabaud-Williamson M, Netchine I, Fasola S, et al. Ovarian-sparing surgery for ovarian teratoma in children. *Pediatr Blood Cancer* 2011;57:429–34.
- [8] Bergeron LM, Bishop KC, Hoefgen HR, et al. Surgical management of benign adnexal masses in the pediatric/adolescent population: an 11-year review. *J Pediatr Adolesc Gynecol* 2017;30:123–7.
- [9] Braungart S, Craigie RJ, Losty PD. Controversies in the management of ovarian tumours in prepubertal children – a BAPS and UK CCLG surgeons Cancer group National Survey. *J Pediatr Surg* 2018;53(11):2231–4.
- [10] Yasui T, Hayashi K, Mizunuma H, et al. Factors associated with premature ovarian failure, early menopause and earlier onset of menopause in Japanese women. *Maturitas* 2012;72:249–55.
- [11] Lokkegaard E, Jovanovic Z, Heitmann BL, et al. The association between early menopause and risk of ischaemic heart disease: influence of hormone therapy. *Maturitas* 2006;53:226–33.
- [12] National Osteoporosis Foundation. Physician's guide to prevention and treatment of osteoporosis. Washington, D.C.: National Osteoporosis Foundation: American Academy of Orthopaedic Surgeons; 1998.

- [13] Atsma F, Bartelink ML, Grobbee DE, et al. Postmenopausal status and early menopause as independent risk factors for cardiovascular disease: a meta-analysis. *Menopause* 2006;13:265–79.
- [14] Rocca WA, Grossardt BR, Shuster LT, et al. Hysterectomy, oophorectomy, estrogen, and the risk of dementia. *Neurodegener Dis* 2012;10:175–8.
- [15] Hermans AJ, Kluijvers KB, Janssen LM, et al. Adnexal masses in children, adolescents and women of reproductive age in the Netherlands: a nationwide population-based cohort study. *Gynecol Oncol* 2016;143:93–7.
- [16] Brougham J, et al. Interim guideline for the treatment of extracranial germ cell tumours in children and adolescents. *Children's Cancer and Leukaemia Group*; 2018.
- [17] Royal College of Obstetrics and Gynaecology. Management of suspected ovarian masses in premenopausal women. Guideline No. 62 RCOG/BSGE Joint Guideline 1; Nov 2011.
- [18] Medeiros LR, Stein AT, Fachel J, et al. Laparoscopy versus laparotomy for benign ovarian tumor: a systematic review and meta-analysis. *Int J Gynecol Cancer* 2008; 18:387–99.
- [19] Childress KJ, Santos XM, Perez-Milicua G, et al. Intraoperative rupture of ovarian Dermoid cysts in the pediatric and adolescent population: should this change your surgical management? *J Pediatr Adolesc Gynecol* 2017;30:636–40.
- [20] Netzhat CR, Kalyoncu S, Nezhat CH, et al. Laparoscopic management of ovarian dermoid cysts: ten years' experience. *JSL* 1999;3:179–84.
- [21] Braungart S, Collaborators CCLG, Craigie RJ, et al. Ovarian tumours in children: how common are lesion recurrence and metachronous disease? A UK CCLG Surgeons Cancer Group nationwide study. *J Pediatr Surg* 2019. <https://doi.org/10.1016/j.pedsurg.2019.10.059>.
- [22] Social Science Statistics Calculator. <https://www.socscistatistics.com/about/>.